OBSTETRICS

In vivo evidence of significant levator ani muscle stretch on MR images of a live childbirth

Nikhil Sindhwani, MS; Christian Bamberg, MD; Nele Famaey, PhD; Geertje Callewaert, MD; Joachim W. Dudenhausen, PhD; Ulf Teichgräber, PhD; Jan Deprest, MD, PhD

OBJECTIVE: Vaginal childbirth is believed to be a significant risk factor for the development of pelvic floor dysfunction later in life. Previous studies have explored the use of medical imaging and simulations of childbirth to determine the stretch in the levator ani muscle. A report in 2012 has recorded magnetic resonance images of a live childbirth of a 24 year old woman giving birth vaginally for the second time, using a 1.0 Tesla open, high-field scanner. Our objective was to determine the stretch ratios in the levator muscle using these magnetic resonance images of live childbirth.

STUDY DESIGN: Three-dimensional magnetic resonance image sequences were obtained to visualize coronal and axial planes before and after the childbirth. These images were obtained before the expulsion phase without pushing and were used to reconstruct the levator muscle and the fetal head in 3 dimensions. The fetal head was approximated to be an ellipsoid, and it is assumed that its middle section is visible in dynamic magnetic resonance images. Assuming incompressibility, the full deformation field of the fetal head is then calculated. Real-time cine magnetic resonance images were acquired for the during the expulsion phase, occurring over 2 contractions in the midsagittal plane. The levator muscle stretch is estimated using a custom program. The program calculates points of contact between the fetal head ellipsoid and the levator ani muscle model as the head descends down the birth canal and moves them orthogonal to its surface. Circumferential stretch was calculated to represent the extension needed to allow the passage of the fetal head.

RESULTS: Starting from a position in the preexpulsion phase, the levator muscle experiences a maximum circumferential stretch of 248% on the posterior-medial portion of the levator ani muscle, as shown in previously published finite element simulations. However, the maximal stretch was notably less than that predicted by finite element models. This is because our baseline 3-dimensional model of the levator muscle is created from images taken shortly before expulsion and thus is already in a stretched state. Furthermore, the finite element models are created from images of a healthy nulliparous woman, while this study uses images from a para 2 woman.

CONCLUSION: This study is the first attempt to estimate the stretch in levator ani muscle using magnetic resonance images of a live childbirth. The stretch was significant and the locations corroborate with previous findings of finite element models.

Key words: childbirth, levator ani muscle, magnetic resonance imaging, pelvic floor dysfunction, vaginal childbirth

Pelvic organ prolapse (POP) is the descent of pelvic organs from their normal position resulting in protrusion of the vagina and/or the uterus.[1] It affects almost half of all middle-aged women to some degree, and can have a significant impact on their quality of life.[1,2] The support to the pelvic organs is provided, next to the bony pelvis, by a complex interplay of pelvic floor musculature, the vaginal wall, connective tissue, fascia, and ligaments. It is widely accepted that the loss of one or more support structures causes POP.

Cite this article as: Sindhwani N, Bamberg C, Famaey N, et al. In vivo evidence of significant levator ani muscle stretch on MR images of a live childbirth. Am J Obstet Gynecol 2017;217:194.e1-8.

0002-9378/$36.00
© 2017 Elsevier Inc. All rights reserved.
http://dx.doi.org/10.1016/j.ajog.2017.04.014

Related editorial, page 110.

Click Video under article title in Contents at **ajog.org**

One event that inflicts direct trauma to the pelvic floor muscle support, the levator ani muscle (LAM), is pregnancy, labor, and in particular vaginal delivery.[3] Levator avulsion is a common form of trauma that has been directly associated with childbirth and causes significant changes in the shape and size of the urogenital hiatus.[4,5]

In an attempt to visualize the mechanisms of this injury, theoretical computational models have been previously presented. These models have shown that the LAM experiences tremendous stretch, almost 3.5 times.[6-8] However, these predictions are difficult to corroborate experimentally because of the lack of real measurements that would require one to record the stretches during childbirth.

In 2012 magnetic resonance (MR) images of a live childbirth were recorded using a 1.0 Tesla open, high-field scanner.[9] In this study, several MR images were collected, including a real-time cinematic MR imaging series in the midsagittal plane (see Figure 1). Also, multislice (3-dimensional [3D]) sequences in the sagittal, coronal, and axial planes were collected before the childbirth. Using these images, Bamberg et al[9] described the relationship between fetal movements and position as the fetus passes through the birth canal.

This study aimed to interpret the stretch occurring in the LAM using this unique MR image data of a live childbirth. With reasonable assumptions, this provides us a first insight into the mechanisms of the LAM stretch during childbirth, as corroborated with the MR images.

Materials and Methods

A 24 year old woman giving birth for the second time, at 37 5/7 weeks of gestation, was admitted with regular contractions to the Department of Obstetrics of the Charité University Hospital in Berlin, Germany. Her height was 165 cm and

FIGURE 1
Dynamic MR image sequence of a live childbirth

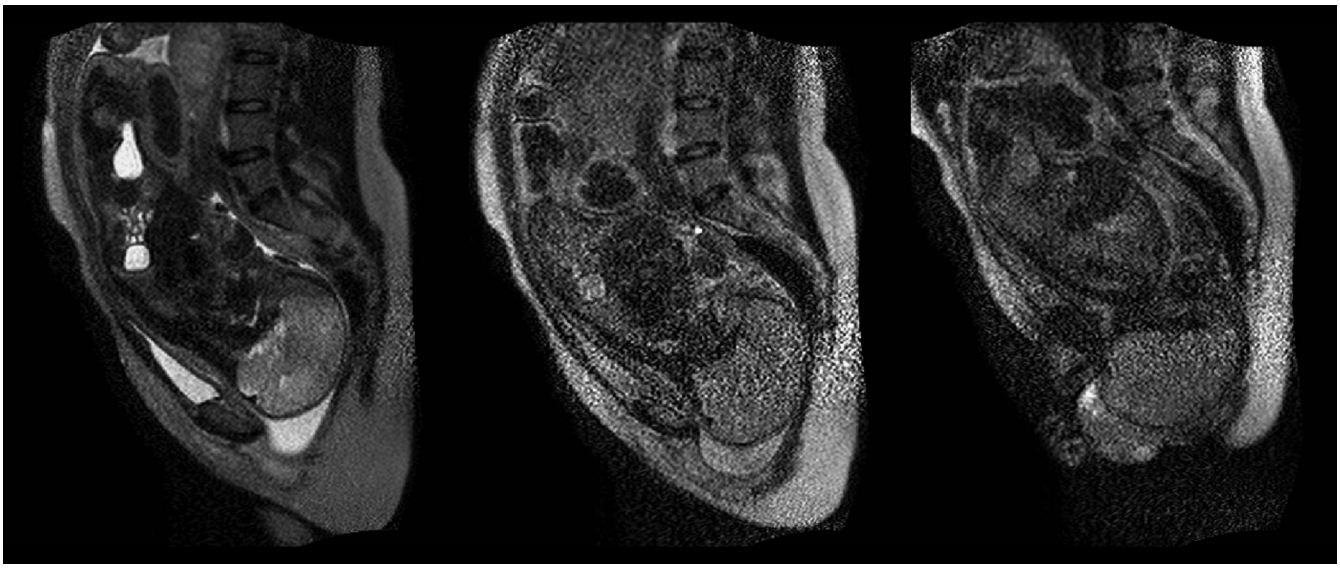

Sindhwani et al. Levator ani muscle stretch on MR images of a live childbirth. Am J Obstet Gynecol 2017.

weight 54 kg before pregnancy and 66 kg at term. She had no diabetes and did not smoke.

After the administration of an epidural, 8 MR sequences were obtained. The detailed image acquisition protocol was published earlier (Bamberg et al, 2012[9]). In brief, the MR sequences included real-time dynamic MR images in the midsagittal plane (6 mm thickness, voxel size 1.4 × 1.5 mm) in the active second stage of labor. This dynamic sequence captures the entire duration of fetal head expulsion.

Also, T2-weighted multislice turbo-spin echo sequences were obtained to visualize the coronal and axial planes early in labor yet before expulsion (40 slices, 6 mm thickness, and 1 mm inter-slice gap with resolution 1.4 × 1.6 mm).

Ethical approval of the study design was obtained, and written informed consent was obtained from the patient at 28 weeks of gestation.

3D model generation

MR images from the axial multislice sequence taken before birth were used to create 3D models of the LAM and the fetal head. On each frame, the outline

FIGURE 2
3D model generation process

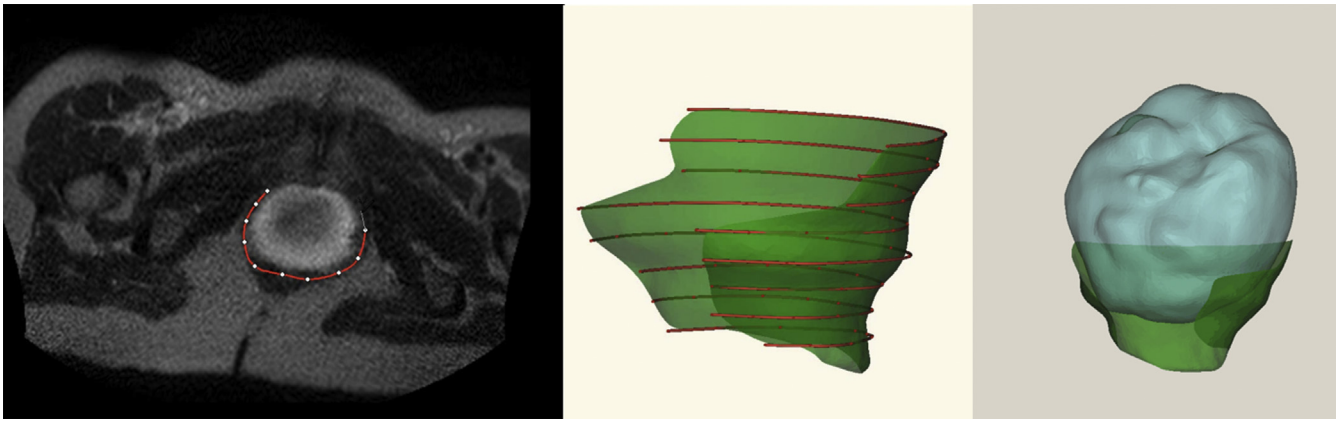

Step 1 is to mark the outline contours of the levator ani muscle and the fetal brain on an axial image sequence (left panel). Step 2 is to interpolate a surface using these curves (middle panel). The resulting 3D models of the fetal brain and the levator ani are shown in the image on the right panel.

3D, 3-dimensional.

Sindhwani et al. Levator ani muscle stretch on MR images of a live childbirth. Am J Obstet Gynecol 2017.

FIGURE 3
Manually outlined fetal brain and an ellipse fitted on it

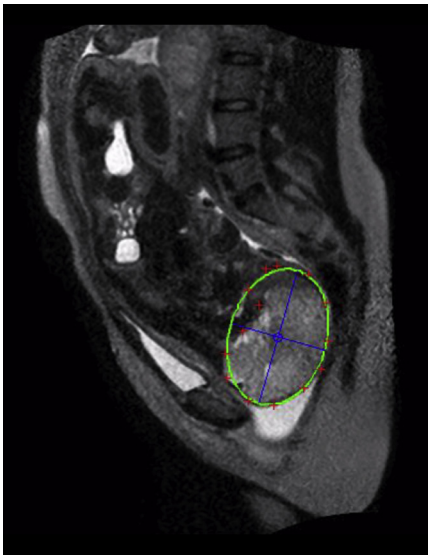

The fetal brain is manually outlined (*red crosses*) and an ellipse is fitted on it (*solid green*). The major axis and minor axes (a and b) are indicated in *blue*. The process is repeated for each frame.

Sindhwani et al. Levator ani muscle stretch on MR images of a live childbirth. Am J Obstet Gynecol 2017.

FIGURE 4
Movement of model's nodes with the descent of ellipsoid head

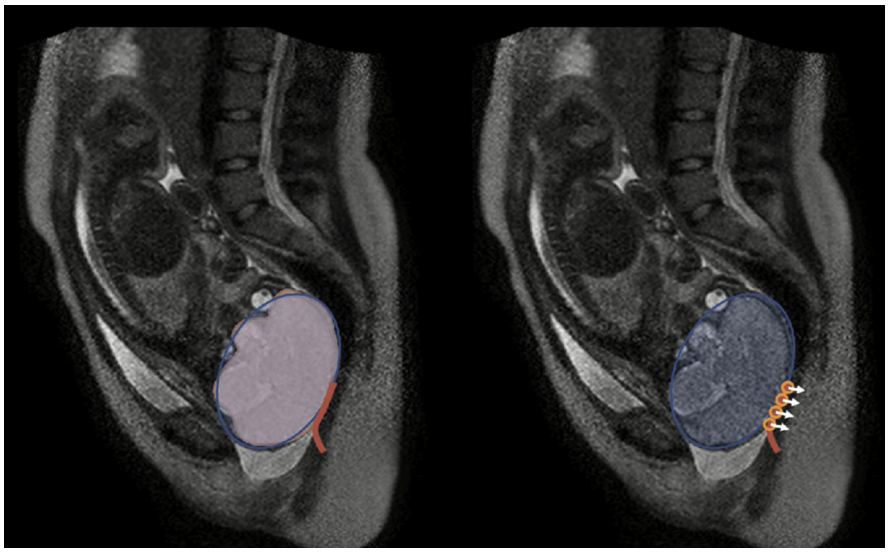

Schematic describing the movement of 3D model's nodes with the descent of the ellipsoid head. Left image shows the outline of the ellipsoid body in *blue* and that of the LAM body in *red*. On the right, *orange circles* signify the nodes of the LAM that are in contact with the ellipsoid head model. The direction of their movement is indicated with *white arrows*.

LAM, levator ani muscle.

Sindhwani et al. Levator ani muscle stretch on MR images of a live childbirth. Am J Obstet Gynecol 2017.

contour of the fetal brain and the LAM were drawn manually, and a 3D surface was extruded on these contours using the Mimics Innovation Suite (MIS version 16; Materialise NV, Leuven, Belgium; see Figure 2). The extent of the LAM that could be extracted from the images may be seen from Appendix A.

The brain was chosen as a proxy to the brain because of its high contrast compared with the skull bones. Also, it is assumed to have a finite unchanging volume. The surface of the 3D models was then interpolated over these curves using design module of the MIS and exported as triangulated surfaces (STL). The models were generated by the lead author (N.S.) and verified by a clinician (G.C.) for accuracy.

Interpretation of the fetal head

The dynamic MR sequence allows visualization of the fetal brain and, by proxy the fetal head, in the midsagittal plane but not in full 3 dimensions. To calculate the stretch occurring in the LAM in 3 dimensions, it is necessary to estimate the 3D extent of the fetal head at each time point. This is achieved by approximating the fetal head as an ellipsoid. The 3D model of the fetal brain is used to get the initial dimensions of the ellipsoid. The net volume of this ellipsoid is assumed to be constant throughout the birth process but can deform according to the changes observed in the fetal head because of head molding during childbirth.

Next, for each frame in the dynamic 2-dimensional midsagittal MR sequence, the brain of the fetus was manually outlined as shown in Figure 3. An ellipse fitted on these 2-dimensional outlines would be the midsagittal cross-section of the full 3D ellipsoid that represents the fetal head. Thus, this ellipse provides the major and minor diameters of this ellipsoid. Using the constant total volume assumption, the third (lateral) diameter of the fetal brain ellipsoid is approximated, giving an estimate of the full 3D extent of the fetal head at each frame. The movement or the descent profile of the centroid of this ellipse, as observed in this midsagittal plane, is also recorded.

Thus, together with the changes in the ellipsoid diameters and the descent profile at each time frame, we obtain the full 3D deformational and translational fields of the fetal head throughout the birth process.

This interpretation process was performed using a custom program in Matlab (version 2013a; Mathworks Inc, Natick, MA).

Anatomical landmark placement

The position of the most inferior point of the pubic symphysis and the tip of the coccyx were marked on each frame. These bony landmark points were used as reference for the position of the fetal head. The final points' positions were averaged over the positions of the points placed by 2 experts (G.C. and C.B.).

Calculation of the LAM stretch

The LAM stretch is estimated by a custom process developed in Matlab. A

FIGURE 5
Long, craniocaudal, and left-right axes of fetal head

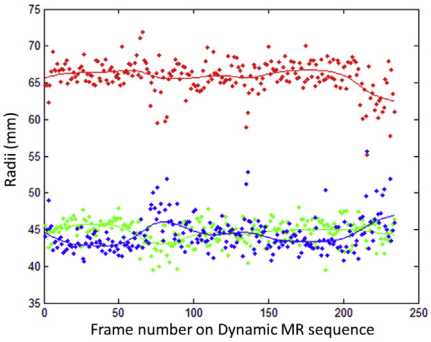

Long axis of the fetal head in *red* **(a)**, craniocaudal axis of the fetal head in *green* **(b)**, and the left-right axis in *blue* **(c)** are shown.

MR, magnetic resonance.

Sindhwani et al. Levator ani muscle stretch on MR images of a live childbirth. Am J Obstet Gynecol 2017.

FIGURE 6
Displacements of the LAM 3D model

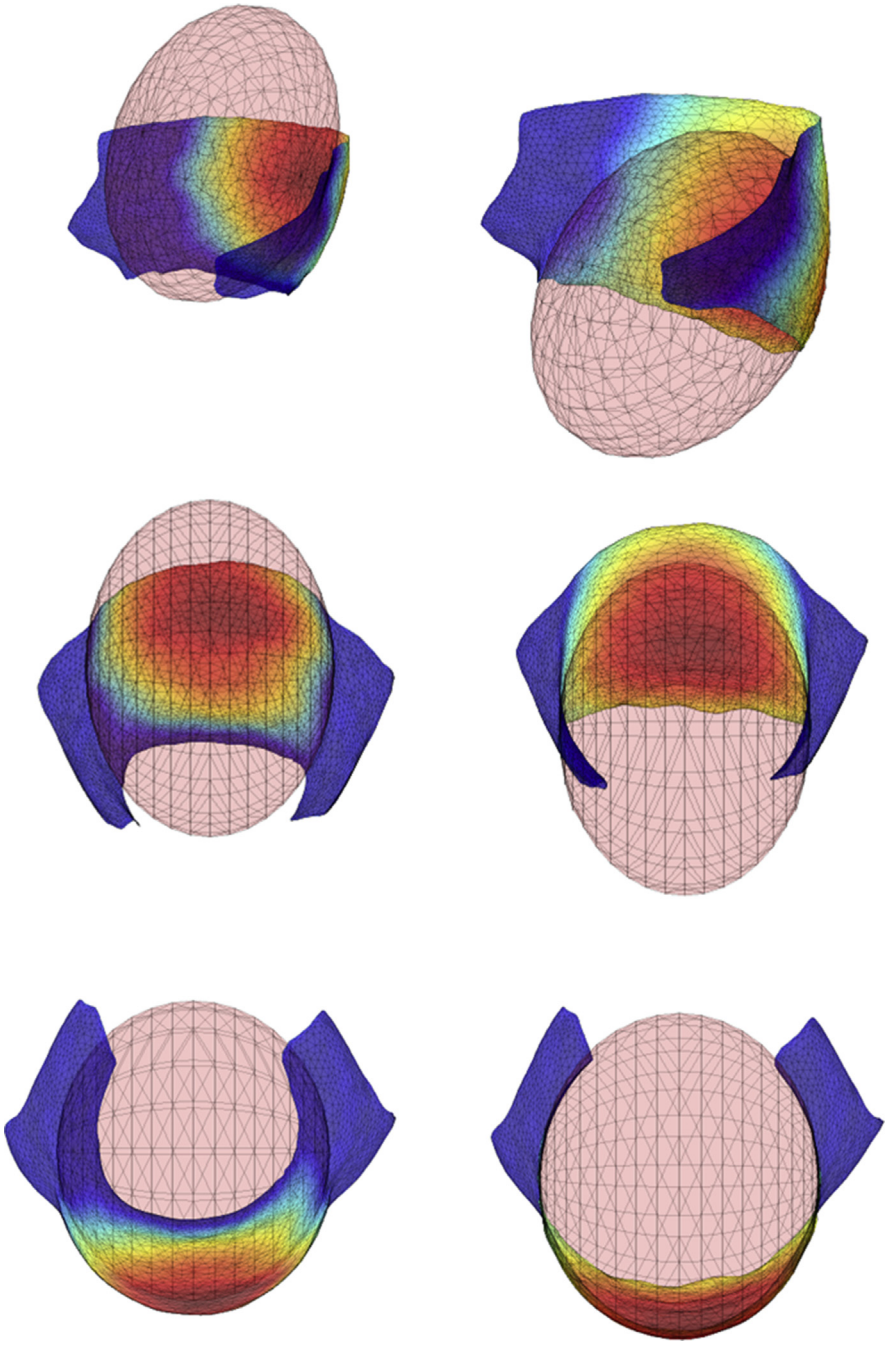

The top, middle, and bottom rows show displacements of the LAM 3D model viewed in the isometric view, frontal view, and caudocranial view, respectively. The left column shows the displacements when the fetal head is midpelvis, and the right column shows the displacements at the time of the expulsion of the head.

3D, 3-dimensional; *LAM*, levator ani muscle.

Sindhwani et al. Levator ani muscle stretch on MR images of a live childbirth. Am J Obstet Gynecol 2017.

translation field is calculated using the anatomical reference points. For each frame, the new position of the fetal head ellipsoid is calculated using the translational and deformation fields recorded from MR images described in the previous text. After this new position is calculated if 1 or more of the vertices of the levator ani 3D object are inside the ellipsoid, they are displaced outward in the direction normal to the LAM's surface. The process is described schematically in Figure 4.

To maintain a continuous surface topology, it was smoothed using the curvature flow smoothing technique after every deformation step.[10,11] Thus, the 3D model of the LAM morphs to allow the descent of the fetal head ellipsoid and provides the displacement values at every node of the model.

Once the nodal displacements are obtained, the circumferential stretch are visualized in Abaqus Finite element software (Simulia; Dassault Systèmes, Paris, France). This is achieved by conducting a trivial simulation in which the displacement is explicitly applied to each node as a boundary condition to the corresponding nodes of the LAM 3D model. The circumferential stretch map was then visualized.

To record the evolution of the lateral and transversal diameter of the LAM, a cross-section of the LAM 3D model was viewed in the plane of minimal hiatal dimensions. An ellipse fitted on this cross-section and then gives the transverse and lateral diameters of the levator muscle.

FIGURE 7
Circumferential stretch in the levator muscle

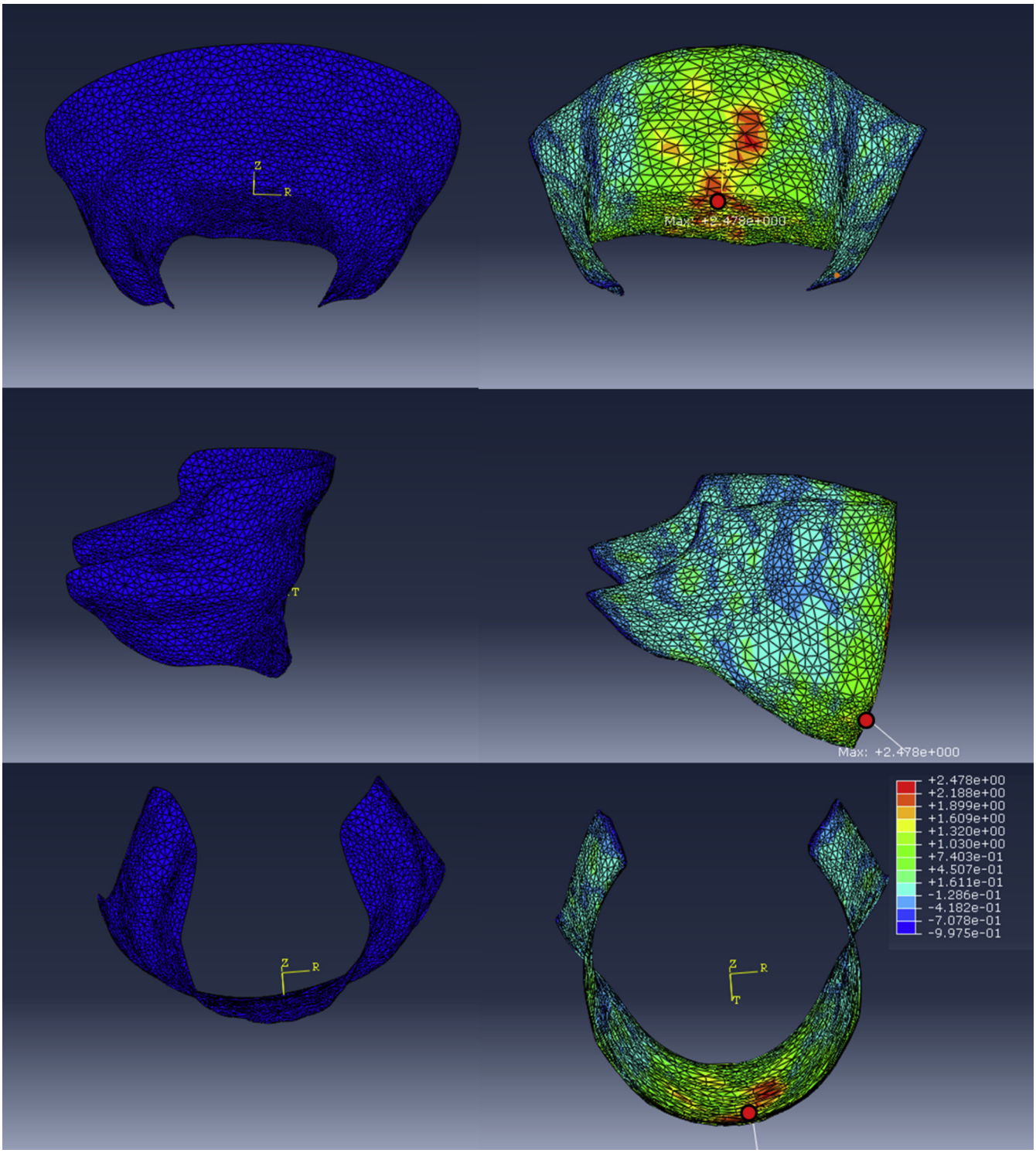

Circumferential stretch in the levator muscle are shown on the right column for 3 different views. The original geometry is shown on the left column for comparison. Maximum stretch recorded was in the LAM region of about 248%, represented with a *red dot*.

LAM, levator ani muscle.

Sindhwani et al. Levator ani muscle stretch on MR images of a live childbirth. Am J Obstet Gynecol 2017.

FIGURE 8
Evolution of lateral and transversal diameter of the LAM

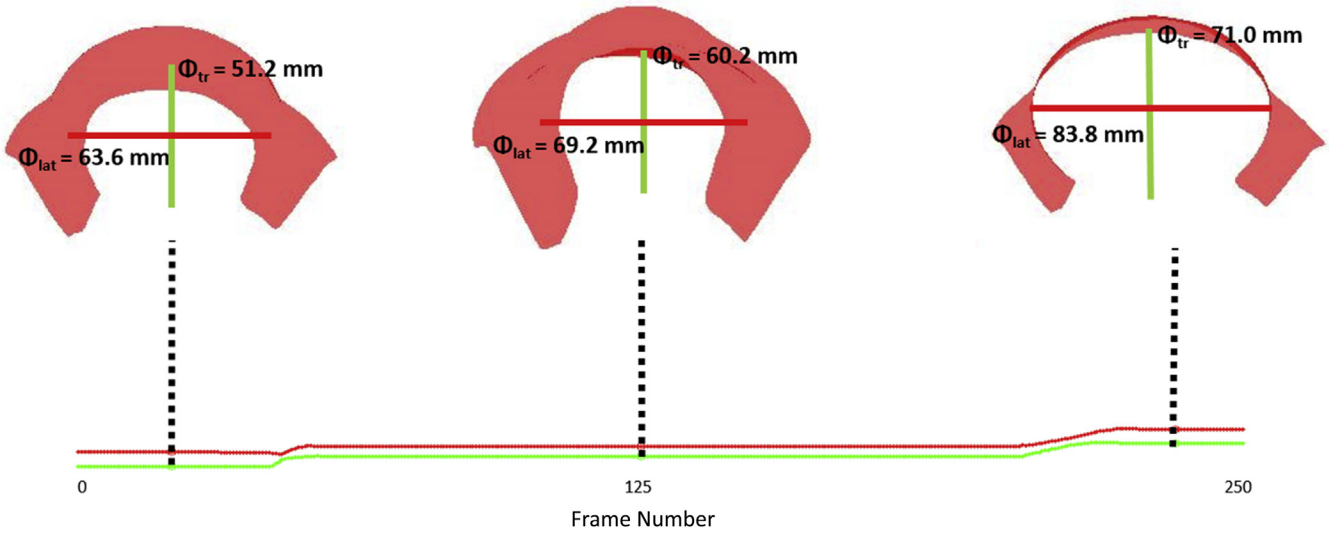

The evolution of the lateral (Φ_{lat}) and transversal diameter (Φ_{tr}) of the LAM as measured in the plane of minimal hiatal dimensions.

LAM, levator ani muscle.

Sindhwani et al. Levator ani muscle stretch on MR images of a live childbirth. Am J Obstet Gynecol 2017.

Results

The image acquisition took a total time of less than 1 hour in the magnet room, and any discomfort during labor was tolerated well. A 2585 g boy was born with a head circumference of 33.5 cm.

The radii of the ellipsoid (A, B, and C) as measured at each image frame are shown in Figure 5. For representation, the plot is smoothed temporally using a spline smoothing function. The radius of the long axis of the fetal head ellipsoid was 65.84 (55.12, 71.87; mean [range]), that of the craniocaudal axis was 44.67 (39.47, 47.00), and that of the left-right axis was 44.33 (40.70 55.64).

Figure 6 shows the displacements occurring in the muscle at 2 different times during the birth, with the relative position of the fetal head ellipsoid.

The circumferential stretch in the levator muscle is shown in Figure 7 from 3 different views. Maximum stretch of 248% was recorded in the posterior caudal region of the LAM muscle. A rendering showing the LAM stretch corresponding to the MR image frames is uploaded in the accompanying video file.

Figure 8 shows the evolution of the lateral and transversal diameter of the LAM as measured in the plane of minimal hiatal dimensions. The lateral diameter extends from 63.6 mm to 83.8 mm, an increase of 31.7%, and the transversal diameter extends from 51.2 mm to 71.0 mm, an increment of 38.7%.

Comment

It is widely accepted that vaginal delivery is a major cause for POP and its symptoms. LAM is a major biomechanical support structure and undergoes tremendous stretch during childbirth. Abdool et al[5] showed that in almost 21% of parous women with symptoms of POP, an avulsion of the levator muscle could be observed.

LAM trauma is believed to be a major reason for the onset of pelvic organ prolapse later in life.[5,12] Furthermore, it has been shown that women who exhibit significant cystocele and who have a LAM injury, are at a higher risk of recurrence following surgical repair.[13] While several computer models have been proposed to estimate the stretch that occur in this region, they have not been verified with data from a real human.

This study reports an estimate of the stretch in the LAM as interpreted directly from MR image data of a live childbirth. To the best of our knowledge, this is a first study to describe the stretch in the LAM that solely relies on real MR image data.

We acknowledge several shortcomings of this study. First, the analysis presented here is based on a dynamic MR sequence recorded in the midsagittal plane. These dynamic images were taken in only 1 plane, as is the limitation of currently available MR imaging hardware. We circumvented this problem by using an ellipsoid approximation of the fetal head and assuming incompressibility of the contents of this ellipsoid. Furthermore, the 3D sequences taken before childbirth have a large interslice distance and relatively low resolution (voxel size is 1.5 mm). This stems from the limiting need to scan using very fast MR protocols. Because of these factors, the 3D models used here are interpolated and not extremely accurate.

Second, we note that the stretch reported in this study is not as high as presented by previous finite element studies. Hoyte et al[6] reported a stretch factor of 3:1, and Lien et al[7] reported a stretch factor of 3.26:1. Nonetheless, the location of the maximum stretch region,

found at the posterior-medial portion of the LAM, however, matches with that predicted by finite element simulations.[7,14]

One must note, however, that both those studies used 3D models of the LAM generated from nulliparous women, while the subject in our study was delivering for the second time vaginally. Shek et al[15] showed that in comparison with the nonpregnant nulliparous women, a para 1 woman in her third trimester is likely to have a hiatal area that is 27% larger at rest. Although there is evidence that this area may reduce again over time, almost 70% women tend to retain a LAM that is larger compared with nulliparous women.[15-17] Moreover, our starting LAM model is generated from MR images taken earlier in labor. These reasons may account for the discrepancy that our measurements fail to match the stretch reported by earlier finite element studies.

Conclusion

The stretch occurring in LAM during childbirth has been reported before, using finite element simulations.[6,7] In this study we calculated the stretch using MR image data of live childbirth. The maximum circumferential stretch observed was about 250 %. The location of the maximum stretch was at the posterior-medial portion of the LAM, as was also shown by finite element simulations. ■

References

1. Jelovsek JE, Maher C, Barber MD. Pelvic organ prolapse. Lancet 2007;369:1027-38.
2. Nygaard IE, McCreery R, Brubaker L, et al. Abdominal sacrocolpopexy: a comprehensive review. Obstet Gynecol 2004;104:805-23.
3. Dietz HP. The aetiology of prolapse. Int Urogynecol J Pelvic Floor Dysfunct 2008;19:1323-9.
4. Dietz HP, Lanzarone V. Levator trauma after vaginal delivery. Obstet Gynecol 2005;106:707-12.
5. Abdool Z, Shek KL, Dietz HP. The effect of levator avulsion on hiatal dimension and function. Am J Obstet Gynecol 2009;201:89.e1-5.
6. Hoyte L, Damaser MS, Warfield SK, et al. Quantity and distribution of levator ani stretch during simulated vaginal childbirth. Am J Obstet Gynecol 2008;199:198.e1-5.
7. Lien K-C, Mooney B, DeLancey JOL, Ashton-Miller JA. Levator ani muscle stretch induced by simulated vaginal birth. Obstet Gynecol 2004;103:31-40.
8. Parente MPL, Jorge RMN, Mascarenhas T, Fernandes AA, Martins JAC. Deformation of the pelvic floor muscles during a vaginal delivery. Int Urogynecol J Pelvic Floor Dysfunct 2008;19:65-71.
9. Bamberg C, Rademacher G, Güttler F, et al. Human birth observed in real-time open magnetic resonance imaging. Am J Obstet Gynecol 2012;206:505.e1-6.
10. Desbrun M, Meyer M, Schröder P, Barr AH. Implicit fairing of irregular meshes using diffusion and curvature flow. Available at: ftp://ftp.cis.upenn.edu/pub/cis610/public_html/Desbrun-DMSB_SIG99.pdf. Accessed May 17, 2017.
11. Kroon D.J. Smooth triangulated mesh. 2005. Available at: https://nl.mathworks.com/matlabcentral/fileexchange/26710-smooth-triangulated-mesh. 2005. Accessed June 10, 2016.
12. Shek KL, Pirpiris A, Dietz HP. Does levator avulsion increase urethral mobility? Eur J Obstet Gynecol Reprod Biol 2010;153:215-9.
13. Dietz HP, Chantarasorn V, Shek KL. Levator avulsion is a risk factor for cystocele recurrence. Ultrasound Obstet Gynecol 2010;36:76-80.
14. Ashton-Miller JA, Delancey JOL. On the biomechanics of vaginal birth and common sequelae. Annu Rev Biomed Eng 2009;11:163-76.
15. Shek KL, Kruger J, Dietz HP. The effect of pregnancy on hiatal dimensions and urethral mobility: an observational study. Int Urogynecol J 2012;23:1561-7.
16. Veelen GA, Van, Schweitzer KJ, Van der Vaart CH. Ultrasound imaging of the pelvic floor: changes in anatomy during and after first pregnancy. 2014;44;476-80.
17. Shek KL, Dietz HP. The effect of childbirth on hiatal dimensions. 2009;113:1272-78.

Author and article information

From the Department of Development and Regeneration, Cluster Organ Systems, Faculty of Medicine (Drs Sindhwani, Callewaert, and Deprest), and Department of Mechanical Engineering (Dr Famaey), Biomechanical Section, KU Leuven, Leuven, Belgium; the Department of Obstetrics (Drs Bamberg and Dudenhausen), Charite University Medicine Berlin, and Department of Radiology (Dr Teichgräber), Friedrich Schiller University, Jena, Germany.

Received Dec. 9, 2016; revised March 25, 2017; accepted April 5, 2017.

Dr Deprest is a fundamental clinical researcher for the Fonds Wetenschappelijk Onderzoek Vlaanderen (grant 1801207). Dr Sindhwani receives a doctoral grant in the Bip-Upy Project (grant NMP3-LA-2012-310389; FP7) supported by the European Commission. The other authors report no conflict of interest.

Presented at the 41st annual meeting of the International Urogynaecological Association in Cape Town, South Africa, and was awarded the best video presentation prize.

Corresponding author: Jan Deprest, MD, PhD. Jan.Deprest@uzleuven.be

APPENDIX A
A label map showing the extent of levator muscle segmented from MR images

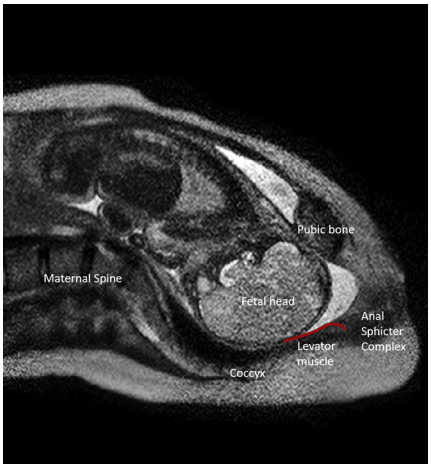

Appendix Figure shows a frame of the dynamic MR image sequence with the midsagittal profile of the LAM model overlaid onto it. The *red contour* is the profile of the LAM model used in the study.

LAM, levator ani muscle; *MR*, magnetic resonance.

Sindhwani et al. Levator ani muscle stretch on MR images of a live childbirth. Am J Obstet Gynecol 2017.